



PATIENT PRESENTING CLINICAL SIGNS

Peanut Nauth History: Suspected PLE.

SPECIES Physical Examination: N/A.

Canine Urinalysis: N/A

CBC: N/A.

BREED Serum Biochemistry: Hypoalbuminemia, elevated liver enzyme activity.

Yorkshire terrier Radiographic Findings: N/A.

SEX ULTRASONOGRAPHIC EXAMINATION OF THE ABDOMEN

MN *Urinary System*

Age Full urinary bladder with a normal thickness and appearance of the wall. Normal anechoic urine with no sediment or uroliths evident.

14 years Normal trigone area, proximal urethra (0.3 cm), and iliac blood vessels.

WEIGHT Normal iliac lymph nodes (0.9 cm). Ureters not visualized.

9 # Normal renal size (left 3.6 cm, right 4 cm) with increased echogenic appearance, some loss of cortico-medullary differentiation and normal pelvis and capsule.

INTERPRETED BY *Reproductive System*

Remo Lobetti, BVSc, MMedVet (Med), PhD, Dipl. ECVIM Small hypoechogenic prostate (0.5 cm).

IMAGING PERFORMED BY *Adrenal Glands*

Sonya Myers, DVM Normal position, echogenic appearance, shape, and size. Left 0.54/0.54 cm, right 0.47 cm.

HOSPITAL NAME *Spleen*

Oviedo Veterinary Care and Emergency Normal size (1.2 cm) and echogenic appearance. Smooth homogenous parenchyma, regular curvilinear capsule, and normal vasculature. No evidence of inflammatory, neoplastic, infarction, or infiltrative changes noted.

REFERRING VET *Liver*

Dr Chow Enlarged with rounded edges, diffuse mottled echogenic appearance, loss of portal markings, and regular curvilinear capsule. Hyperechogenic parenchymal irregular nodules/masses evident – 1.3 x 2.1 cm, 1 x 1.4 cm, and 1.1 x 2.8 cm in size. FNA taken with no obvious post-aspirate hemorrhage. Gall bladder not evident – poorly defined hyperechogenic structure (0.8 cm) in the region of the gall bladder. Normal bile duct (0.2 cm).

INVOICE

303776

DATE

1/17/23


PATIENT *Gastrointestinal*

Peanut Nauth

Normal appearance of the duodenum, ileo-cecal junction, and colon with no loss of layering, normal wall thickness (duodenum 0.47 cm, colon 0.15 cm) and peristaltic activity, and no distension of the lumen. Segmental thickening of the stomach (0.67 cm) and small intestine (0.46 cm) with no loss of layering or distention of the lumen. Mucosal stippling within the small intestine.

SPECIES

Canine

Pancreas
BREED

Yorkshire terrier

Enlarged (left 1.8 cm, right 1.2 cm) with a hypoechogenic appearance and irregular capsule. Hyperechogenic appearance of the mesentery and fat surrounding the pancreas.

Free Abdomen
SEX

Mesenteric lymphadenomegaly (0.6 x 1.4 cm) with normal echogenic appearance and shape.

MN

Small amount of acellular ascites.

Age

14 years

ULTRASONOGRAPHIC FINDINGS

Primary Findings:

WEIGHT

9 #

- Pancreatitis.
- Nodular hepatopathy.
- Gastroenteropathy
- Mesenteric lymphadenomegaly.
- Ascites.
- Mesenteric inflammation.

INTERPRETED BY

Remo Lobetti, BVSc,
MMedVet (Med), PhD, Dipl.
ECVIM

Secondary Findings:

- Age-related renal changes.
- Absent gall bladder.

IMAGING PERFORMED BY

Sonya Myers, DVM

HOSPITAL NAME

Oviedo Veterinary Care and
Emergency

INTERPRETATION OF THE FINDINGS & FURTHER RECOMMENDATIONS

The appearance of the pancreas is consistent with pancreatitis.

Etiologies for the hepatopathy would be nodular hyperplasia, granulomatous disease, chronic hepatitis, and neoplasia.

REFERRING VET

Dr Chow

Etiologies for the gastroenteropathy would be secondary to the pancreatitis, non-specific (viral, bacterial, parasitic, toxins, dietary indiscretion), lymphangectasia, ulcerative disease, granulomatous disease, inflammatory bowel disease, dietary hypersensitivity, and emerging lymphoma.

INVOICE

303776

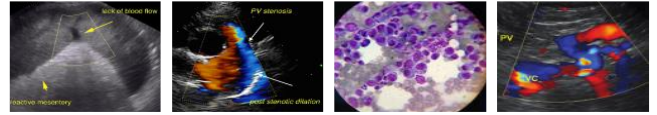
The lymphadenomegaly, ascites, and mesentery inflammation can all be ascribed as secondary to the pancreatitis, hepatopathy, and/or gastroenteropathy.

DATE

1/17/23

Further assessment needs to be based on the pending cytology results but could include fecal analysis, cPL/PSL assay, 3-view thoracic radiographs, and endoscopy of the upper GI tract with biopsies.

Specific therapy would be dependent on an etiological diagnosis.



PATIENT

Peanut Nauth

SPECIES

Canine

BREED

Yorkshire terrier

SEX

MN

Age

14 years

WEIGHT

9 #

INTERPRETED BY

Remo Lobetti, BVSc,
MMedVet (Med), PhD, Dipl.
ECVIM

IMAGING PERFORMED BY

Sonya Myers, DVM

HOSPITAL NAME

Oviedo Veterinary Care and
Emergency

REFERRING VET

Dr Chow

INVOICE

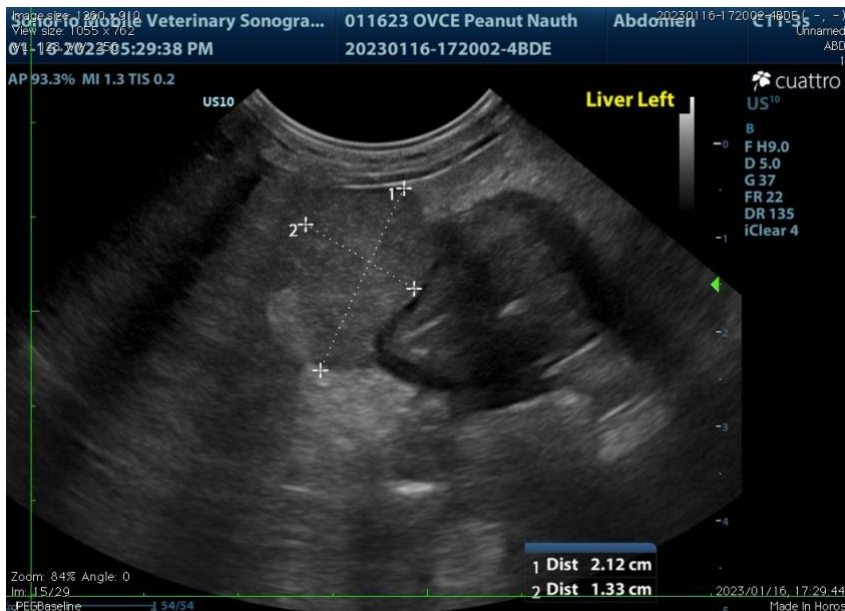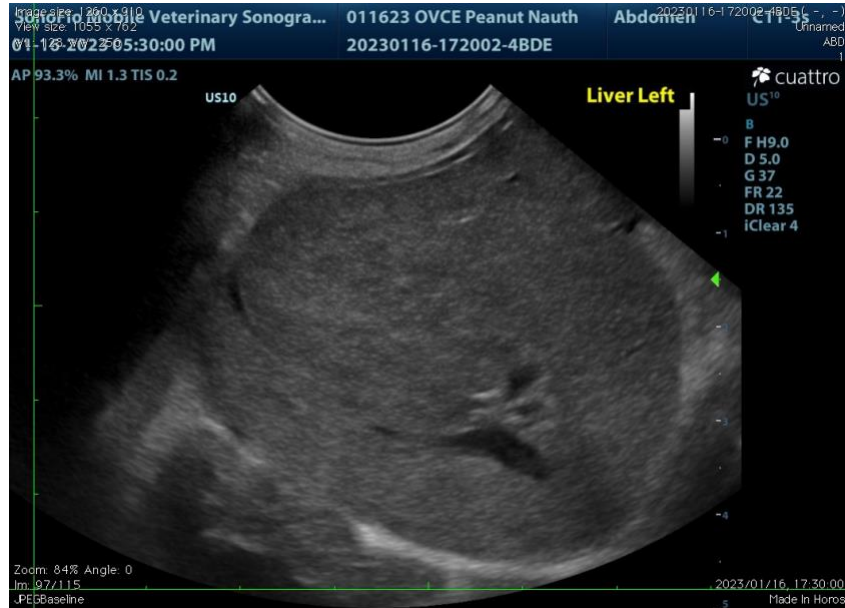303776

DATE

1/17/23

IMAGES

Liver





PATIENT Stomach

Peanut Nauth

SPECIES

Canine

BREED

Yorkshire terrier

SEX

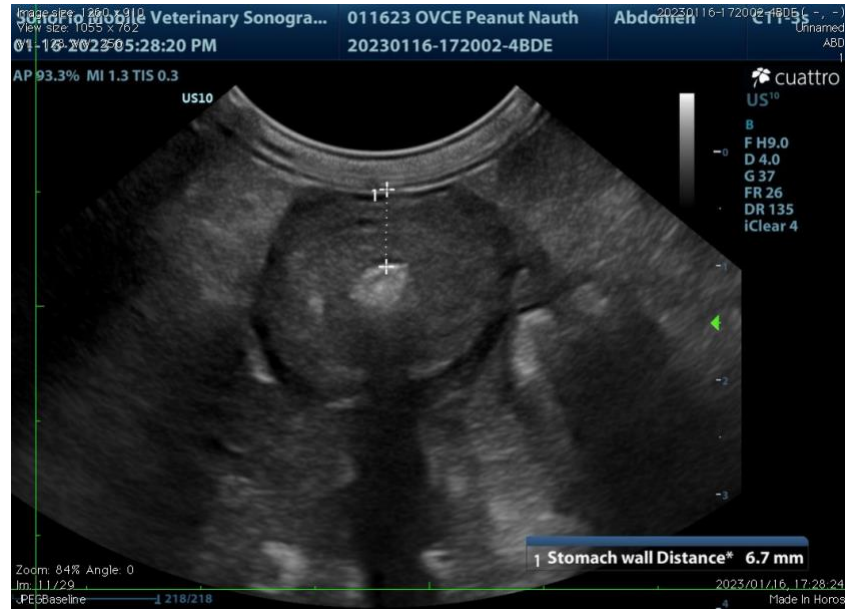MN

Age

14 years

WEIGHT

9 #



Jejunum

INTERPRETED BY

Remo Lobetti, BVSc,
 MMedVet (Med), PhD, Dipl.
 ECVIM

IMAGING PERFORMED BY

Sonya Myers, DVM

HOSPITAL NAME

Oviedo Veterinary Care and
 Emergency

REFERRING VET

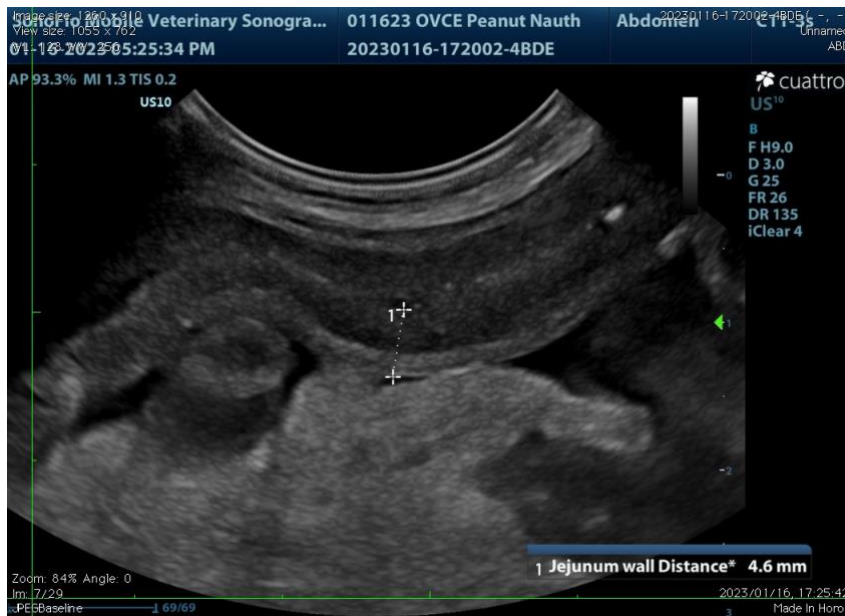Dr Chow

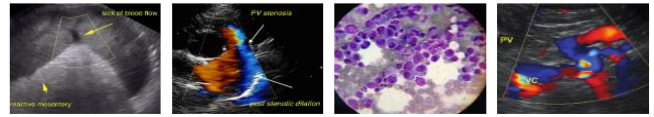
INVOICE

303776

DATE

1/17/23





PATIENT Pancreas

Peanut Nauth

SPECIES

Canine

BREED

Yorkshire terrier

SEX

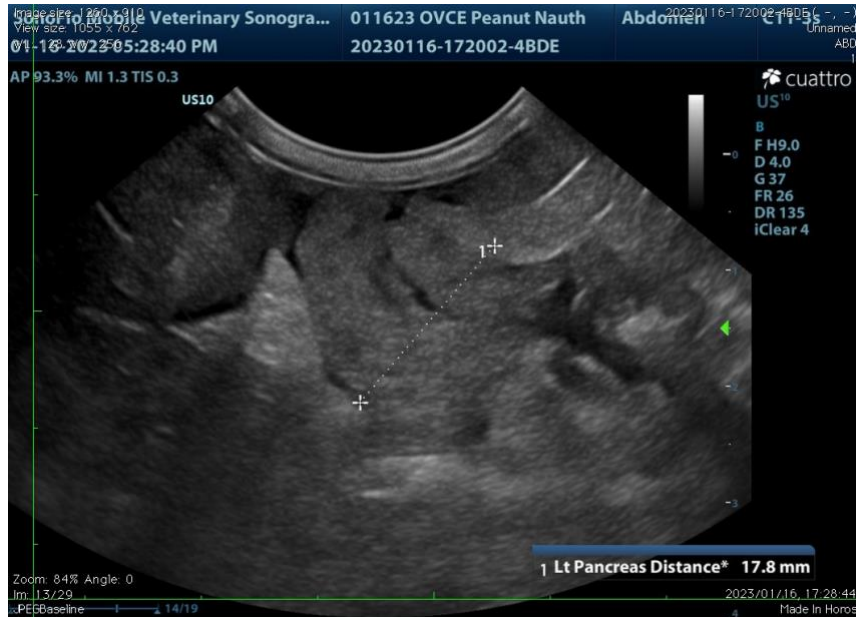MN

Age

14 years

WEIGHT

9 #



INTERPRETED BY

Remo Lobetti, BVSc,
MMedVet (Med), PhD, Dipl.
ECVIM

The information and recommendations provided are based on the images presented by the referring veterinarian. No evaluation can be communicated regarding pathology that was not visible in the image/video clips provided.

Thank you for this referral. If the clinical or image interpretation does not parallel your findings or if I can be of any further assistance, please contact me.

Remo Lobetti, BVSc, MMedVet (Med), PhD, Dipl. ECVIM (Internal Medicine)
robetti@mweb.co.za

IMAGING PERFORMED BY

Sonya Myers, DVM

HOSPITAL NAME

Oviedo Veterinary Care and
Emergency

REFERRING VET

Dr Chow

INVOICE

303776

DATE

1/17/23